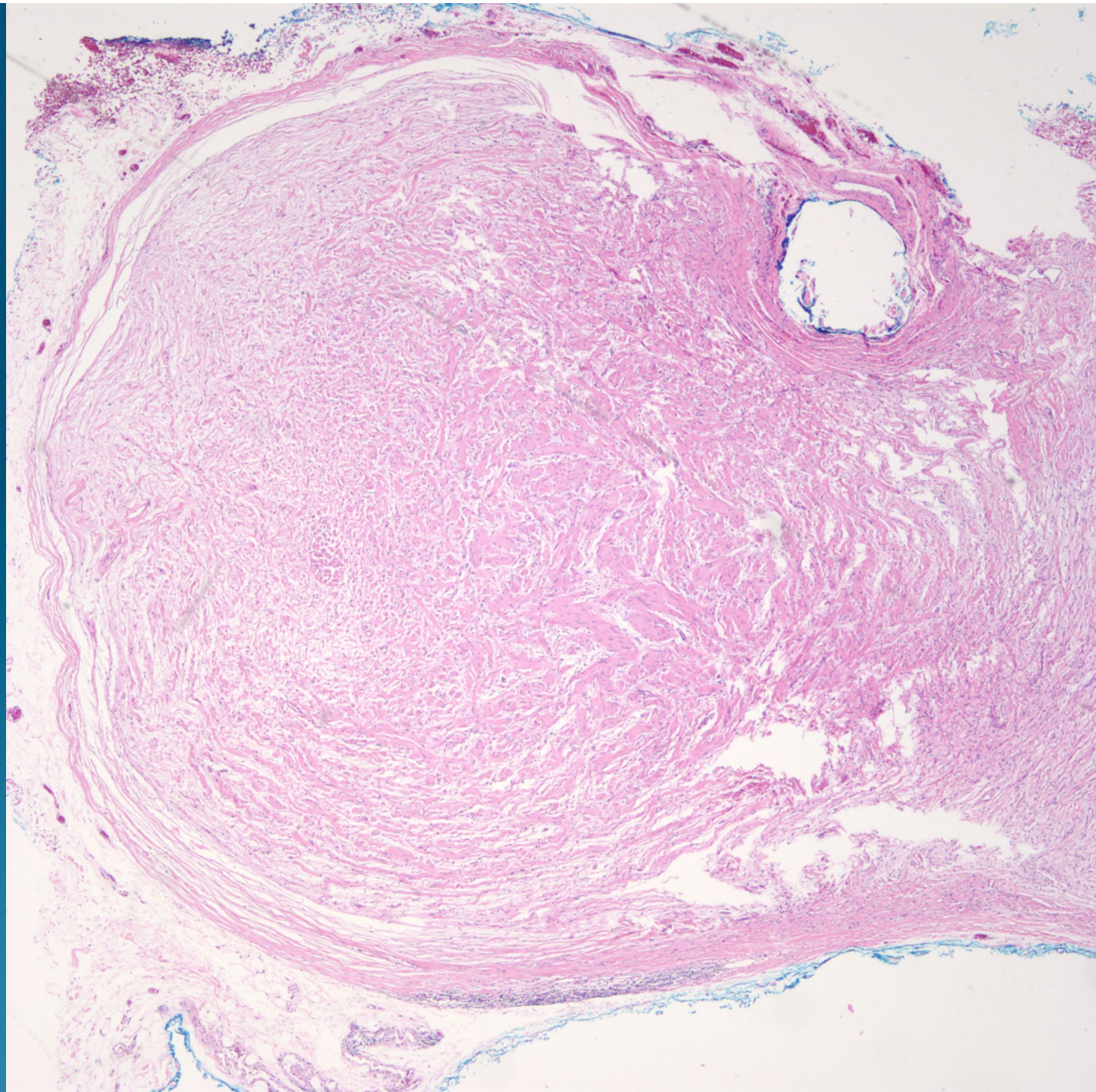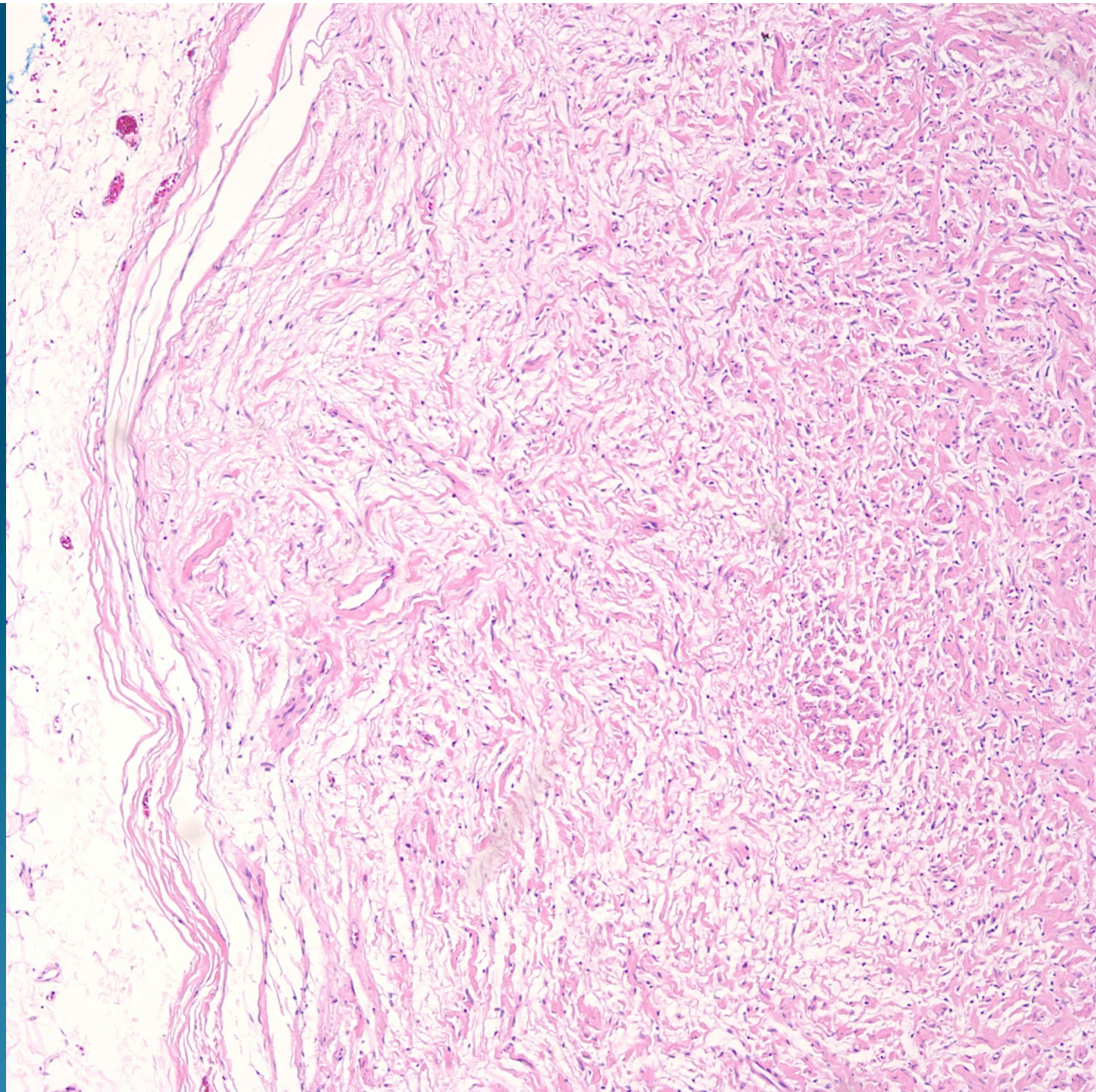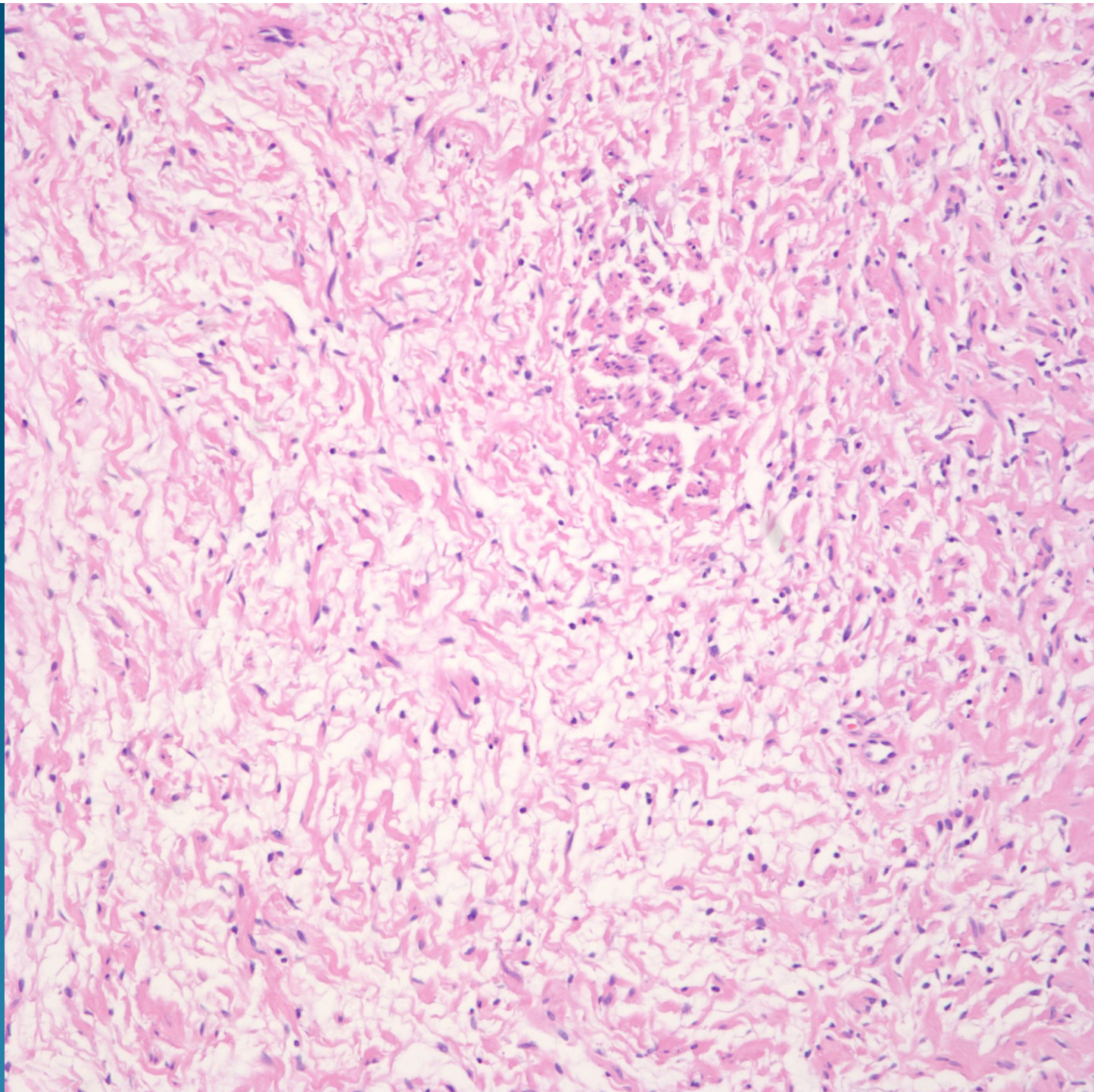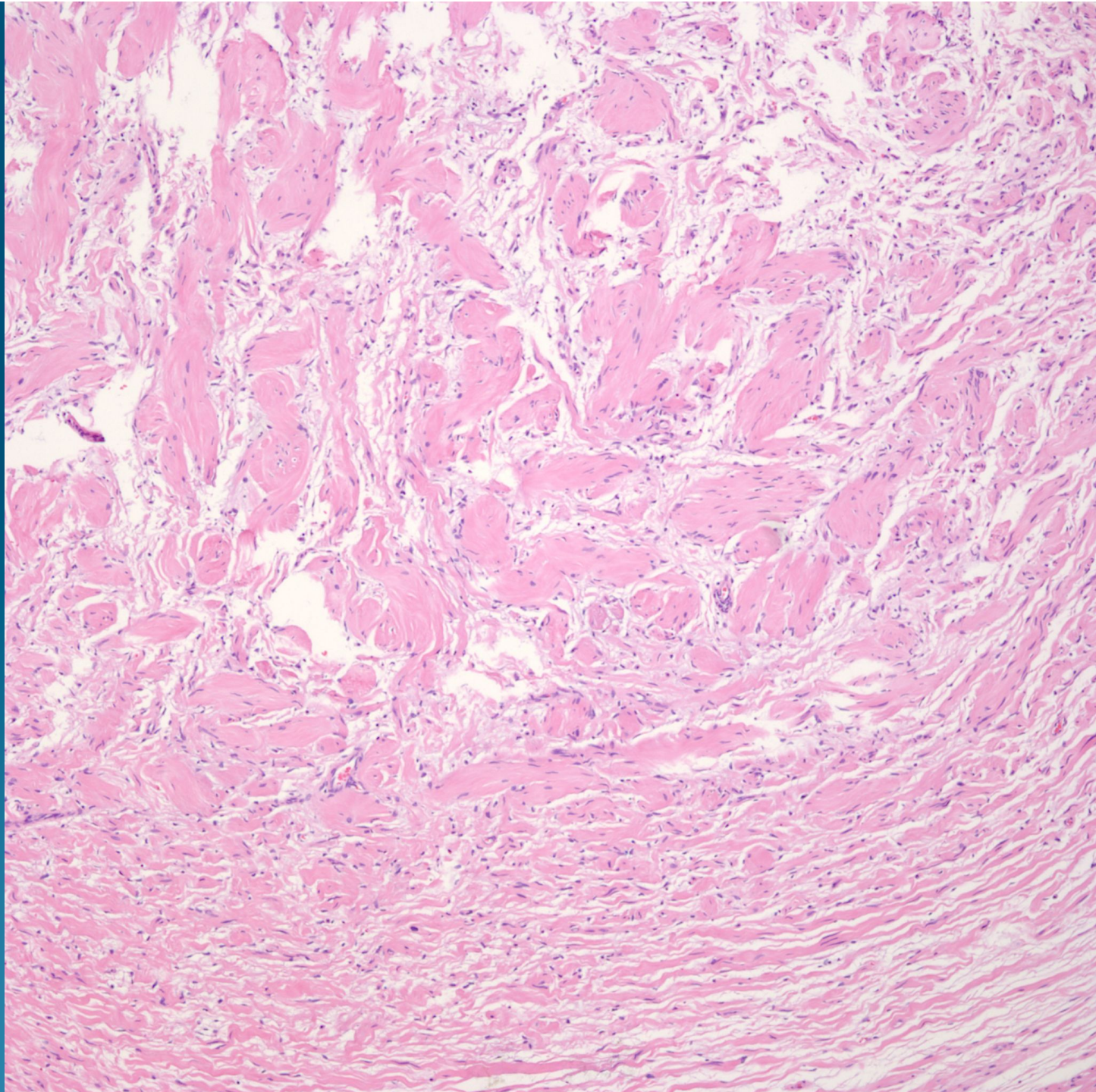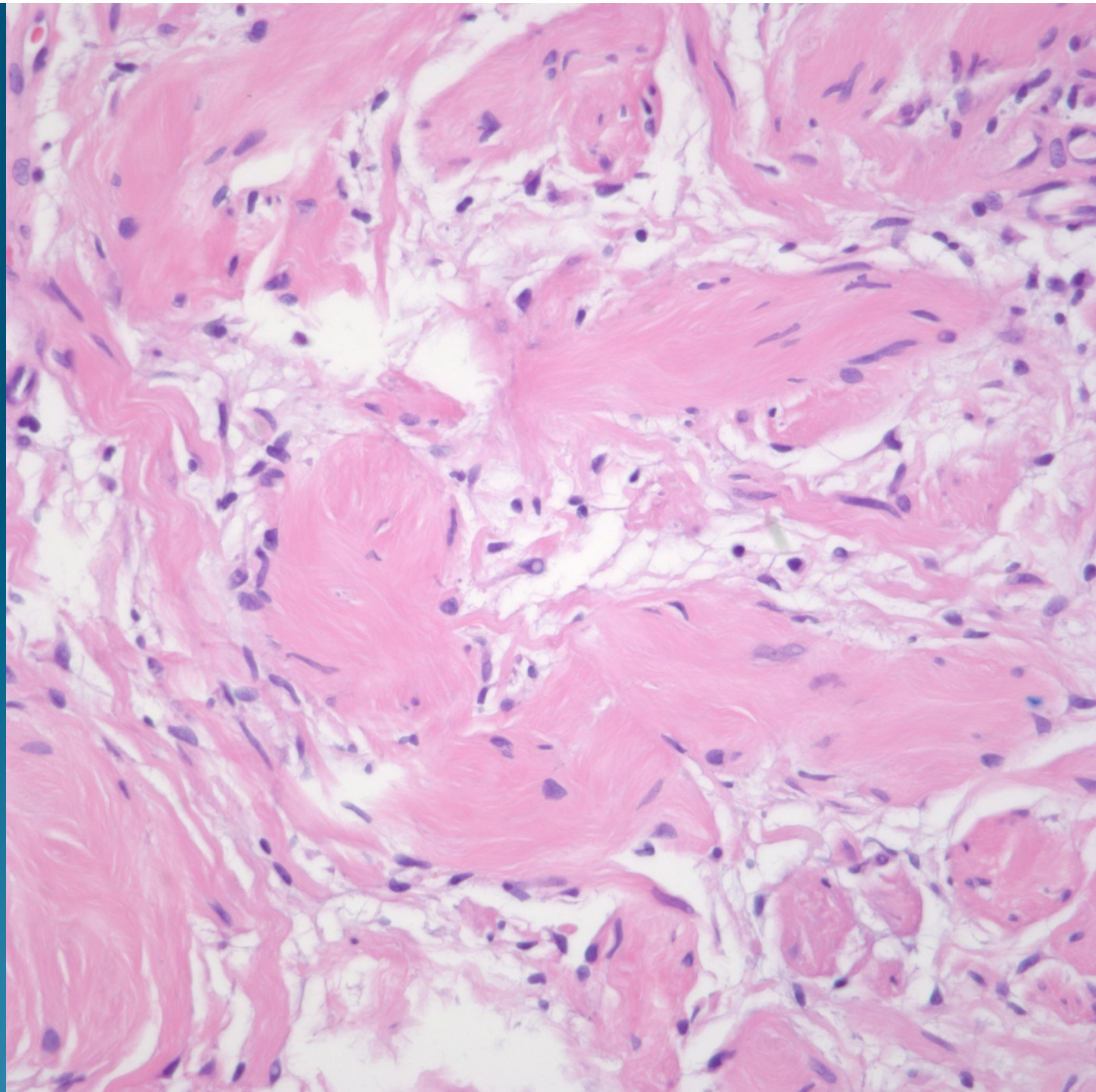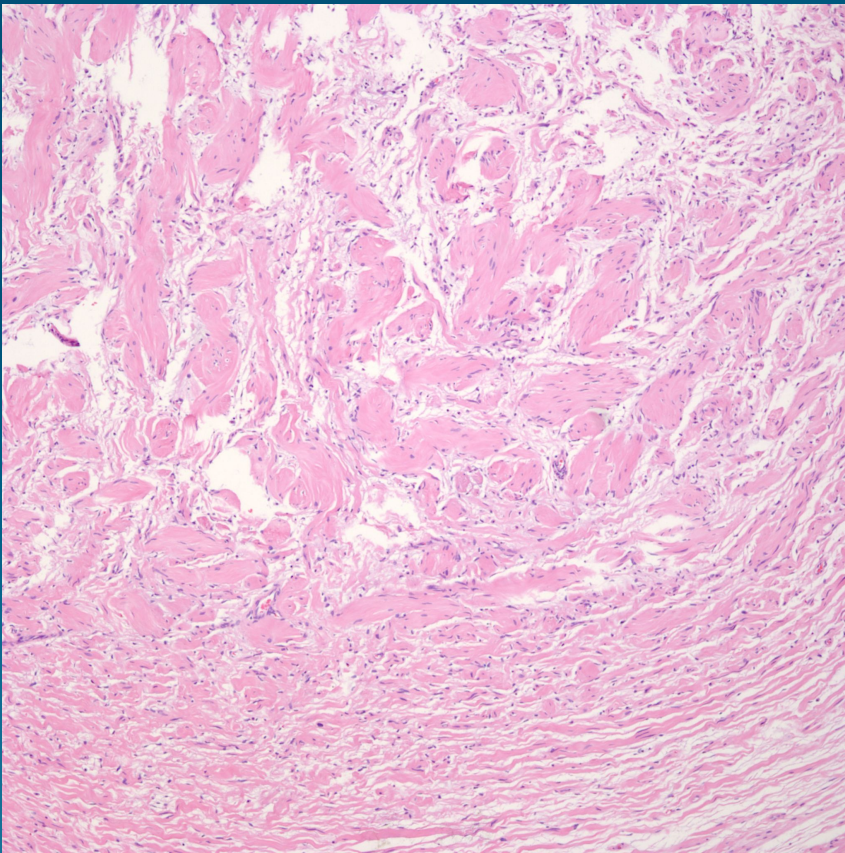


What is the best diagnosis?

- A. Neurofibroma
- B. Neurilemmoma
- C. Palisaded and encapsulated neuroma
- D. Traumatic neuroma
- E. Desmoplastic melanoma

Neurilemmoma (Cutaneous Schwannoma)

Pearls



- Circumscribed spindle cell tumor, usually deeper dermis or subcutaneous fat
- Bland spindle cells with wavy nuclei
- Arranged in cellular palisading areas (Antoni A) and myxoid loose pattern (Antoni B)